

# Ultra-Low Microcurrent Therapy: A Novel Approach for Treatment of Chronic Resistant Wounds

**Bok Y. Lee, MD, FACS**

Department of Surgery  
New York Medical College  
Valhalla, New York

**Keith Wendell, PhD**

American Institute of Regeneration  
Simi Valley, California  
Mt. Tamborine QLD, Australia

**Noori Al-Waili, MD, PhD**

Department of Surgery  
North Shore University Hospital  
Manhasset, New York

**Glenn Butler, CHT**

Life Support Technology Group  
Mount Vernon Hospital  
Sound Shore Health System  
Mount Vernon, New York

## ABSTRACT

This study was undertaken to investigate the efficacy of ultra-low microcurrent delivered by the Electro Pressure Regeneration Therapy (EPRT) device for the management of chronic wounds. In this study, 23 patients with chronic skin ulcers and 2 with abdominal dehiscence that was present for an average of 16.5 mo, who were not responsive to standard conservative treatment in a hospital setting, were treated with the EPRT device. Wounds were treated with direct current (maximum of 3 mA) of 1 polarity for 11.5 min and then with a current of the opposite polarity for another 11.5 min. Treatment was applied through ultra-low microcurrents (in the mA to nA range) conducted through special wraps applied above and below the wound. The results revealed that 34.8% of cases achieved complete wound healing after an average of 45.6 h of treatment, and 39.1% achieved  $\geq 50\%$  healing after an average of 39.7 h of treatment. Several patients achieved significant results after 1 to 2 treatments. The EPRT device not only accelerated healing but also appeared to negate the effect of a person's age on wound healing.

**Keywords:** I ultra-low microcurrent; ulcer; wound; antioxidants

## INTRODUCTION

Problems in wound healing continue to cause significant morbidity and mortality. It has been shown that high-voltage and low-pulsed electrical currents augment wound healing.<sup>1-5</sup> Electrical stimulation, which has been shown to clearly enhance healing of pressure ulcers in a significant number of individuals with spinal cord injury,<sup>6</sup> has shown beneficial effects during the inflammatory, proliferation, and maturation phases of a wound.<sup>5</sup>

Recently, microcurrent stimulation has received attention as another type of electrotherapy that has proven effective in wound healing. Microcurrent electrical neuromuscular stimulation, a subsensory modality that employs current intensities between 1 and 999  $\mu\text{A}$ , has been successfully used to enhance soft-tissue healing and to treat fracture nonunion.<sup>7-9</sup> Electrical stimulation at 20  $\mu\text{A}$ , which induces the flow of electrons into the skin and subcutaneous injury, can effect wound healing.<sup>10</sup> Electroacupuncture treatment, a technique that uses stimulation of acupuncture needles with a low-frequency microcurrent, suppresses myostatin expression, which leads to a satellite cell-related proliferative reaction and repair in skeletal muscle.<sup>11</sup> Cranial electrotherapy stimulation, a noninvasive technique that delivers a microcurrent to the brain via ear clip electrodes, has effectively treated several neurologic and psychiatric disorders; it can effectively treat chronic pain in those with spinal cord injury and is considered to be an effective agent for the treatment of fibromyalgia.<sup>12,13</sup>

In a study by El-Husseini et al,<sup>14</sup> microcurrent skin patch therapy after total knee arthroplasty led to better pain control with a markedly decreased need for tramadol as compared with the control group. This was accompanied by better wound healing and lower drain volume.<sup>14</sup> Further, microcurrent relieves myocontracture and can enhance conventional rehabilitation programs for children with cerebral palsy.<sup>15</sup> Studies from the 1980s suggest that microcurrent therapy is effective at relieving the adverse effects of radiation therapy.<sup>16</sup> A total of 26 patients with head and neck cancer who were experiencing the late effects of radiotherapy were treated with impedance-controlled microcurrent therapy for 1 wk. At the end of the course of microcurrent therapy, 92% of 26 patients exhibited improved cervical rotation, 85% had improved cervical extension/flexion, and 81% had improved cervical lateral flexion.<sup>17</sup> Treatment of 30 healthy men with induced muscle damage by means of Accustat electromembrane microcurrent therapy reduced symptom severity.<sup>18</sup> Microcurrent stimulation relieves the pain in temporomandibular joints through internal derangement.<sup>19</sup>

Microcurrent treatment, at an output of 100  $\mu\text{A}$  and at individual subsensory levels, effectively reduced postexercise creatine kinase levels after induction of muscle damage.<sup>20</sup> In addition, the results showed enhanced soft tissue healing and treatment of fracture nonunion after subsensory electrostimulation.<sup>7-9</sup> Accustat reduces some of the clinical features of delayed-onset muscle soreness. The mechanisms of action are not known but may be related to a reduction in disturbance of intracellular  $\text{Ca}^{2+}$ .

This clinical trial was conducted to evaluate the safety and efficacy of the Electro Pressure Regeneration Therapy (EPRT) device for healing of stage II to IV ulcers that have shown no significant response to conventional therapy over a period of  $\geq 3$  mo.

## PATIENTS AND METHODS

The EPRT is an electrical device that sends a pulsating stream of electrons in a relatively low concentration throughout the body. The device is noninvasive and delivers electrical currents that are compatible with the natural electrical energy of the human body. It is a battery-operated device that delivers a direct current (maximum of 3 mA) of 1 polarity for 11.5 min and then switches to the opposite polarity for another 11.5 min. The device produces a current range of 3 mA down to 100 nA. The frequency used produces a cycle that lasts approximately 23 min. The device was designed to switch the direction of current flow halfway through the cycle. It runs on a rechargeable battery that produces a square wave bipolar current with voltage ranging from 5 V up to a maximum of 40 V. Electrodes are applied in 2 layers, and tap water is used as the conducting medium. The wraps cover a large surface area, thus reducing resistance and allowing an optimum number of electrons to flow freely into tissues.

A total of 25 patients with chronic wounds that were present for a period ranging from 3 to 60 mo were treated. Patient age ranged from 20 to 85 y. Assessment of ulcers was based on the scale used by the National Pressure Ulcer Advisory Panel Consensus Development Conference. In all, 18 lesions were stage III or IV, and 3 were stage II. The 4 remaining wounds were not staged. Lesions were present for an average of 18.5 mo. Associated conditions of chronic wounds included acquired immune deficiency syndrome, arterial insufficiency, cerebrovascular accident, chronic obstructive pulmonary disease, chronic renal failure, congestive heart failure, spinal cord injury, traumatic brain injury, and venous stasis (Table). Patients were treated for approximately 3.5 h/d, 5 d/wk, until the lesions had healed. A 12-wk maximum was allowed for healing to take place. All patients were inpatients and were on wound care treatment for at least 3 mo prior to the start of this study; no improvement in their condition was observed. For 23 min/d, patients were wrapped, above and below the wound, with the spongy bandage soaked in water. Conductive silicone electrodes were then wrapped over these and attached to the device with stud clips. For the first cycle, the device was set at a current output of 3  $\mu$ A. For the subsequent 8 cycles of treatment, the device was set at an output of 400 nA, and treatment was continued for 3 h. The rate of wound closure was measured by reduction in size in square centimeters per day. The rate of closure for the 3 groups was then averaged (younger than 50 y, between 50 and 70 y, and older than 70 y). Comparisons were also made between the length of time that the lesion was present and the length of time that treatment was provided.

## RESULTS

Of the 25 patients who were treated for chronic wounds, 9 were younger than 50 y, 8 were between 50 and 70, and 8 were older than 70 y. Among these 25 lesions, 23 were caused by pressure. The average healing rate for the 3 age groups was measured in centimeters per day as follows: 20 to 49 y—0.74 cm<sup>2</sup>/d; 50 to 70 y—0.73 cm<sup>2</sup>/d; and older than 70 y—0.73 cm<sup>2</sup>/d.

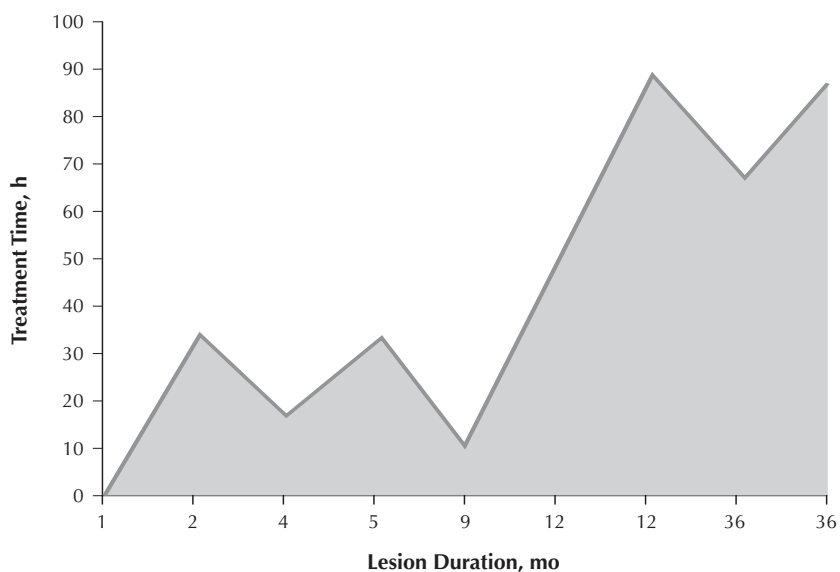
The length of treatment necessary for complete healing was directly proportional to the duration of the lesion (Fig 1). Although no surgical debridement was performed, all necrotic tissue appeared to reabsorb spontaneously and was replaced with healthy granulation tissue and/or skin. Of all the stage III/IV lesions, 7 healed completely over a period of treatment (18–91 h, with an average of 50.5 h of treatment).

## Summary of Patient Data and Response to Microcurrent Therapy

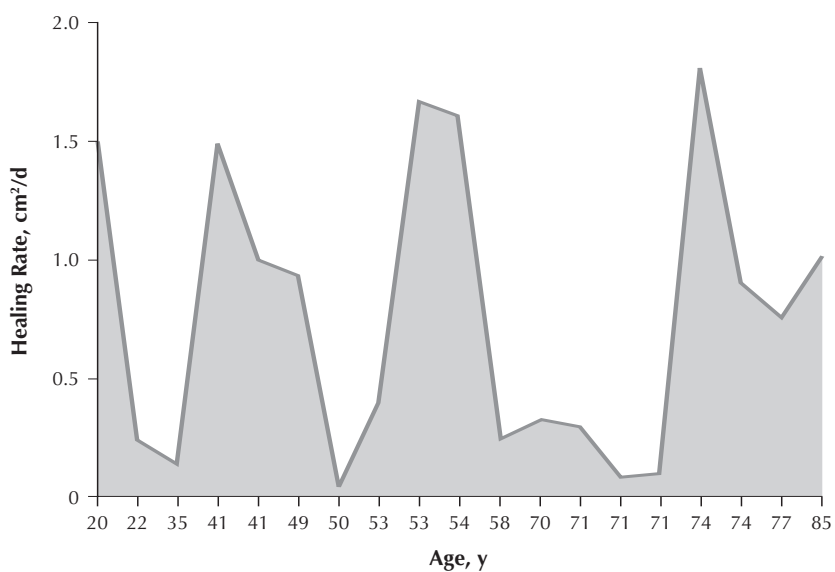
Results	No. of Treatments	Lesions	Diseases	Sex	Age, y	Patient No.
Complete healing	10	Stage IV ulcer of right heel for 3 y	Diabetes, COPD	Male	74	1
Complete healing	44	Wound on right foot for 5 y + osteomyelitis	Diabetes	Male	50	2
Complete healing	30	Stage III lesion of right knee for 3 y	Diabetes, renal failure, hypertension	Male	71	3
Drastically decreased in diameter	12	Stage IV ulcer of right hip for 6 mo	HIV, PVD, paraplegia	Male	41	4
Complete healing	10	Stage III lesion of left knee for 2 mo	Diabetes, renal failure, hypertension	Male	71	5
Drastically decreased in diameter	12	Stage IV lesion of left hip for 8 mo	HIV, PVD, paraplegia	Male	41	6
Complete healing	5	Stage IV sacral ulcer for 4 mo	Quadriplegia	Male	53	7
Complete healing	14	Stage III ulcer of left heel for 1 y	CHF	Female	71	8
Complete healing	26	Stage IV ulcer of left heel for 1 y	Paraplegia	Female	22	9
Complete healing	2	Stage II knee ulcer for 1 mo	COPD, hypertension	Female	77	10
Complete healing	3	Stage II ulcer of left knee for 9 mo	Paraplegia	Male	53	11
Decrease in size	8	Stage IV sacral ulcer for 3 mo	Paraplegia	Male	30	12
Healthy clean healed tissue	3	Stage IV sacral ulcer for 3 mo	CVA	Female	72	13
Partially healed	4	Stage III heel ulcer for 6 mo	Respiratory failure	Male	85	14
Complete healing	8	Stage II sacral lesion for 1 mo	Hypertension, COPD	Male	74	15
Complete healing	10	Stage IV ulcer of right heel for 5 mo	Guillain-Barré syndrome	Male	70	16
Partially healed	3	Dehisced abdominal wound for 2 mo	Respiratory failure	Female	56	17
Almost healed	22	Stage IV right gluteal ulcer for 14 mo	Respiratory failure	Male	35	18
Partially healed	3	Stage IV sacral ulcer for 2 y	Spina bifida	Male	36	19
Wound depth decreased from 6 cm to 2 cm	16	Stage IV left gluteal ulcer for 18 mo	Quadriplegia	Male	49	20
Partially healed	4	Stage III ulcer of left hip for 4 mo	Quadriplegia	Female	58	21
Partially healed	3	Dehisced abdominal wound for 3 mo	Subdural hematoma	Female	48	22
Partially healed	5	Ulcer on left outer foot for 3 y	Paraplegia, diabetes	Male	65	23
Partially healed	3	Stage III ankle lesion for 5 y	Brain lesion	Male	54	24
Partially healed	4	Stage IV ulcer of right hip for 7 y	Paraplegia	Male	20	25

CHF=congestive heart failure; COPD=chronic obstructive pulmonary disease; CVA=cerebrovascular accident; HIV=human immunodeficiency virus; PVD=peripheral vascular disease.

**Fig 1. The length of treatment necessary for complete healing was directly proportional to lesion duration.**



**Fig 2. Healing rate as related to patient age.**



An additional 7 lesions healed by  $\geq 50\%$  over an average of 46 h of treatment. The remaining 4 lesions (III/IV) showed clearing of infection and necrotic tissue and influx of healthy granulation tissue, with an average of 26% healing over an average of 15.5 h of treatment. The 3 stage II lesions achieved complete healing over an average of 15 h of treatment. Of the 4 nonstaged wounds, 2 dehiscent abdominal wounds and 1 ulcer of the left foot showed partial healing. Complete healing of the wound on the right foot with osteomyelitis was achieved. The Table summarizes demographic data, wound characteristics, and patient response to ultra-low microcurrent therapy. All patients showed the same response to ultra-low microcurrent therapy regardless of their age, and all age groups showed similar healing rates when treated with ultra-low microcurrent (Fig 2).

## DISCUSSION

Cells have complex electricity that is sensitive to changes in electrical fields. Metabolic, immunologic, and physiologic changes have been found to develop in different cell cultures after electrical current is applied. Endogenous bioelectricity, which includes electrical current and electrical potential, is essential for life. Electrical fields have been shown to control the direction and rate of epithelial cells that migrate into the wound. The investigators found that direct electrical therapy was effective in healing gum abscesses and accelerating wound healing.<sup>21</sup> Substances that increase the electrical field, such as prostaglandin  $E_2$ , enhance the wound healing rate and increase cell division.<sup>22-24</sup> Electrical fields stimulate secretion of growth factor.<sup>24</sup> Low  $\mu A$  current stimulates adenosine triphosphate production.<sup>25</sup> Another study found that microcurrent stimulates dermal fibroblasts and U937 cells to secrete transforming growth factor- $\beta_1$ , which is an important regulator of cell-mediated inflammation and tissue regeneration.<sup>26</sup>

In one study, Accustat electromembrane reduced the severity of symptoms in 30 healthy men with induced muscle damage; the beneficial effects of microcurrent therapy on muscle damage are likely related to maintenance of intracellular  $Ca^{2+}$  homeostasis after muscle-damaging exercise.<sup>18</sup> Further, an increase in collagen concentration has been found in and around the wound. A similar suggestion was reported when microcurrent was used for soft tissue repair.<sup>27</sup> The higher level of intracellular calcium encourages increased synthesis of adenosine triphosphate, and protein synthesis is encouraged by mechanisms that control DNA, thus promoting cellular repair and replication.<sup>25</sup>

Direct and indirect evidence suggests that free radicals play a key role in normal biologic function and in the pathogenesis of certain human diseases. Oxidative stress as a consequence of an imbalance in prooxidant-antioxidant homeostasis in chronic wounds is thought to drive a deleterious sequence of events, finally resulting in the nonhealing state. Because the inflammatory phase does not resolve in chronic wounds, the load of reactive oxygen species persists over a long time with subsequent continuous damage and perpetuation of the inflammation.<sup>28</sup> Patients with chronic lesions due to debilitating disease are expected to have high levels of free radicals. Their wounds are generally necrotic and infected with poor healing potential, again indicating a high concentration of free radicals.

Macrophage-derived cytokines expected at the wound site include tumor necrosis factor and platelet-derived growth factor. Platelet-derived growth factor function

is subject to redox control at multiple levels. Tumor necrosis factor- $\alpha$  biosynthesis has been shown to be reactive oxygen species-inducible as well.<sup>29,30</sup> Actually, the device used in this experiment was supposed to deliver electrons to tissues and then to saturated free radicals with required electrons. The fact that these electrons are focused on a small region of the body may explain why healing changes appeared so rapidly.

The actual tissue regeneration coupled with absence of the age factor in healing, along with concomitant improvement noted in the general condition of the patient, points to a highly potent antioxidant effect on local tissues, as well as on tissues in general. This reduces free radicals and might facilitate tissue repair. Additional studies are needed to substantiate this suggestion. Per the protocol, each patient was considered a control for himself because of the chronicity of the lesions and the patient's lack of responsiveness to conventional therapy; however, the main limitation of the study is the lack of a control group. Therefore, a randomized, controlled study would be the appropriate next component of the current research plan.

## REFERENCES

1. Alvarez M, Mertz M, Smerbeck V, Eaglstein H. The healing of superficial skin wounds is stimulated by external electrical current. *J Invest Dermatol.* 1983;81:144-148.
2. Brown M, McDonnel M, Menton D. Electrical stimulation effects on cutaneous wound healing in rabbits. *Phys Ther.* 1988;68:955-960.
3. Weiss DS, Eaglstein WH, Falanga V. Exogenous electric current reduces the formation of hypertrophic scars. *J Dermatol Surg Oncol.* 1989;15:1272-1275.
4. Bogie KM, Reger SI, Levine SP, Sahgal V. Electrical stimulation for pressure sore prevention and wound healing. *Assist Technol.* 2000;12:50-66.
5. Demir H, Balay H, Kirnap M. A comparative study of the effects of electrical stimulation and laser treatment on experimental wound healing in rats. *J Rehabil Res Dev.* 2004;41:147-154.
6. Baker LL, Rubayi S, Villar F, Demuth SK. Effect of electrical stimulation waveform on healing of ulcers in human beings with spinal cord injury. *Wound Repair Regen.* 1996;4:21-28.
7. Bach S, Bilgrav K, Gottrup F, Jorgensen TE. The effect of electrical current on healing skin incision: an experimental study. *Eur J Surg.* 1991;157:171-174.
8. Carley PJ, Wainapel SF. Electrotherapy for acceleration of wound healing: low intensity direct current. *Arch Phys Med Rehabil.* 1985;66:443-446.
9. Nessler JP, Mass DP. Direct-current stimulation of tendon healing in vitro. *Clin Orthop Relat Res.* 1987;217:303-312.
10. Fleischi G, Lauchlin T. Electrical stimulation in wound healing. *J Foot Ankle Surg.* 1977;36:457-461.
11. Takaoka Y, Ohta M, Ito A, et al. Electroacupuncture suppresses myostatin gene expression: cell proliferative reaction in mouse skeletal muscle. *Physiol Genomics.* 2007;30:102-110.
12. Tan G, Rintala DH, Thornby JI, Yang J, Wade W, Vasilev C. Using cranial electrotherapy stimulation to treat pain associated with spinal cord injury. *J Rehabil Res Dev.* 2006;43:461-474.
13. Lichtbroun AS, Raicer MM, Smith RB. The treatment of fibromyalgia with cranial electrotherapy stimulation. *J Clin Rheumatol.* 2001;7:72-78.
14. El-Husseini T, El-Kawy S, Shalaby H, El-Sebai M. Microcurrent skin patches for postoperative pain control in total knee arthroplasty: a pilot study. *Int Orthop.* 2007;31:229-233.

15. Mäenpää H, Jaakkola R, Sandström M, Von Wendt L. Does microcurrent stimulation increase the range of movement of ankle dorsiflexion in children with cerebral palsy? *Disabil Rehabil.* 2004;26:669-677.
16. King GE, Scheetz J, Jacob RF, Martin JW. Electrotherapy and hyperbaric oxygen: promising treatments for postradiation complications. *J Prosthet Dent.* 1989;62:331-334.
17. Lennox AJ, Shafer JP, Hatcher M, Beil J, Funder SJ. Pilot study of impedance-controlled microcurrent therapy for managing radiation-induced fibrosis in head-and-neck cancer patients. *Int J Radiat Oncol Biol Phys.* 2002;54:23-34.
18. Lambert MI, Marcus P, Burgess T, Noakes TD. Electro-membrane microcurrent therapy reduces signs and symptoms of muscle damage. *Med Sci Sports Exerc.* 2002;34:602-607.
19. Bertolucci LE, Grey T. Clinical comparative study of microcurrent electrical stimulation to mid-laser and placebo treatment in degenerative joint disease of the temporomandibular joint. *Cranio.* 1995;13:116-120.
20. Allen JD, Mattacola CG, Perrin DH. Effect of microcurrent stimulation on delayed-onset muscle soreness: a double-blind comparison. *J Athl Train.* 1999;34:334-337.
21. AL-Waili N. Electrotherapy for chronic gum and periapical abscesses. *J Pak Med Assoc.* 1989;39:161-162.
22. Song B, Zhao M, Forrester V, McCaig D. Electrical cues regulate the orientation and frequency of cell division and the rate of wound healing in vivo. *Proc Natl Acad Sci U S A.* 2002;99:13577-13582.
23. McCaig D, Rajnicek M, Song B, Zhao M. Has electrical growth cone guidance found its potential? *Trends Neurosci.* 2002;25:354-359.
24. Zhao M, Bai H, Wang E, Forrester V, McCaig D. Electrical stimulation directly induces pre-angiogenic response in vascular endothelial cells by signaling through VEGF receptors. *J Cell Sci.* 2003;117:397-405.
25. Cheng N, Van Hoof F, Bockx E, et al. The effects of electric currents on ATP generation, protein synthesis, and membrane transport in rat skin. *Clin Orthop Relat Res.* 1982;171:264-272.
26. Todd I, Clothier RH, Huggins ML, et al. Electrical stimulation of transforming growth factor-beta 1 secretion by human dermal fibroblasts and the U937 human monocytic cell line. *Altern Lab Anim.* 2001;29:693-701.
27. Denegar CD, Pernin DH, Rogol A, Rutt R. Influence of transcutaneous electrical nerve stimulation on pain, range of motion, and serum cortisol concentration in females experiencing delayed onset muscle soreness. *J Orthop Sports Phys Ther.* 1989;1:100-103.
28. Wlaschek M, Scharffetter-Kochanek K. Oxidative stress in chronic venous leg ulcers. *Wound Repair Regen.* 2005;13:452-461.
29. Haddad JJ, Saadé NE, Safieh-Garabedian B. Redox regulation of TNF-alpha biosynthesis: augmentation by irreversible inhibition of gamma-glutamylcysteine synthetase and the involvement of an I-kappaB-alpha/NF-kappaB-independent pathway in alveolar epithelial cells. *Cell Signal.* 2002;14:211-218.
30. Haddad JJ. Redox regulation of pro-inflammatory cytokines and I-kappaB-alpha/NF-kappaB nuclear translocation and activation. *Biochem Biophys Res Commun.* 2002;296:847-856.